



ISUOG

Virtual World Congress

on Ultrasound in Obstetrics and Gynecology

Share your research with our large international ultrasound community including leading names in the field. Submit your abstract for the chance to present orally or via an electronic poster presentation at our Virtual World Congress this October.



Key dates for submission

- 15 June 2021: Abstract submission deadline
- July 2021: Notification of acceptance or rejection
- 16 August 2021: Presenting authors registration deadline

Submit your abstract now





Imaging in gynecological disease (20): clinical and ultrasound characteristics of adnexal torsion

F. MORO^{1#}, G. BOLOMINI^{1#}, M. SIBAL², S. B. VIJAYARAGHAVAN³, P. VENKATESH⁴, F. NARDELLI^{1,5}, T. PASCIUTO¹, F. MASCILINI¹, F. POZZATI^{1,6}, F. P. G. LEONE⁷, H. JOSEFSSON^{8,9}, E. EPSTEIN^{8,9}, S. GUERRIERO¹⁰, G. SCAMBIA^{1,6}, L. VALENTIN^{11,12} and A. C. TESTA^{1,6}

¹Fondazione Policlinico Universitario Agostino Gemelli, IRCCS, Dipartimento Scienze della Salute della Donna, del Bambino e di Sanità Pubblica, Rome, Italy; ²Department of Fetal Medicine and Obstetric and Gynecologic Ultrasound, Manipal Hospital, Bangalore, India; ³Ultrasonic Scan Centre, Coimbatore, India; ⁴Department of Fetal Medicine and OBGYN Ultrasound, Manipal Hospital, Bangalore, India; ⁵Institute for Women's Health, University College Hospital, London, UK; ⁶Istituto di Clinica Ostetrica e Ginecologica, Università Cattolica del Sacro Cuore, Rome, Italy; ⁷Department of Obstetrics and Gynecology, Biomedical and Clinical Sciences Institute L. Sacco, University of Milan, Milan, Italy; ⁸Department of Clinical Science and Education, Karolinska Institutet, Stockholm, Sweden; ⁹Department of Obstetrics and Gynecology, Södersjukhuset, Stockholm, Sweden; ¹⁰Department of Obstetrics and Gynecology, University of Cagliari, Policlinico Universitario Duilio Casula, Monserrato, Cagliari, Italy; ¹¹Department of Obstetrics and Gynecology, Skåne University Hospital, Malmö, Sweden; ¹²Department of Clinical Sciences Malmö, Lund University, Lund, Sweden

KEYWORDS: adnexal torsion; ovarian neoplasms; ovarian torsion; pelvic pain; ultrasonography

CONTRIBUTION

What are the novel findings of this work?

This is the largest series of patients with adnexal torsion described in the literature, with 315 patients evaluated in different countries. On ultrasound, the most common findings were an enlarged adnexa with an ovarian mass, characterized by ovarian stromal edema with or without peripherally displaced antral follicles, the whirlpool sign and free fluid in the pelvis.

What are the clinical implications of this work?

Adnexal torsion represents a surgical emergency. Symptoms and laboratory examinations are often non-diagnostic and similar to those in other diseases. Assessment of ultrasound signs of torsion should be mandatory for counseling and management of the patient, in order not to delay surgery and to direct the patient to the correct specialist.

ABSTRACT

Objectives To describe the clinical and ultrasound characteristics of adnexal torsion.

Methods This was a retrospective study. From the operative records of the eight participating gynecological ultrasound centers, we identified patients with a surgically confirmed diagnosis of adnexal torsion, defined as surgical

evidence of ovarian pedicle, paraovarian cyst and/or Fallopian tube twisted on its own axis, who had undergone preoperative ultrasound examination by an experienced examiner, between 2008 and 2018. Only cases with at least two available ultrasound images and/or videoclips (one grayscale and one with Doppler evaluation) were included. Clinical, ultrasound, surgical and histological information was retrieved from each patient's medical record and entered into an Excel file by the principal investigator at each center. In addition, two authors reviewed all available ultrasound images and videoclips of the twisted adnexa, with regard to the presence of four predefined ultrasound features reported to be characteristic of adnexal torsion: (1) ovarian stromal edema with or without peripherally displaced antral follicles, (2) the follicular ring sign, (3) the whirlpool sign and (4) absence of vascularization in the twisted organ.

Results A total of 315 cases of adnexal torsion were identified. The median age of the patients was 30 (range, 1–88) years. Most patients were premenopausal (284/314; 90.4%) and presented with acute or subacute pelvic pain (305/315; 96.8%). The surgical approach was laparoscopic in 239/312 (76.6%) patients and conservative surgery (untwisting with or without excision of a lesion) was performed in 149/315 (47.3%) cases. According to the original ultrasound reports, the median largest diameter of the twisted organ was 83 (range,

Correspondence to: Dr F. Moro, Fondazione Policlinico Universitario A. Gemelli, IRCCS, Dipartimento Scienze della Salute della Donna, del Bambino e di Sanità Pubblica, L.go A. Gemelli 8, 00168 Rome, Italy (e-mail: morofrancy@gmail.com)

#F.M. and G.B. contributed equally to this study.

Accepted: 14 January 2020

30–349) mm. Free fluid in the pouch of Douglas was detected in 196/275 (71.3%) patients. Ovarian stromal edema with or without peripherally displaced antral follicles was reported in the original ultrasound report in 167/241 (69.3%) patients, the whirlpool sign in 178/226 (78.8%) patients, absent color Doppler signals in the twisted organ in 119/269 (44.2%) patients and the follicular ring sign in 51/134 (38.1%) patients. On retrospective review of images and videoclips, ovarian stromal edema with or without peripherally displaced antral follicles (201/254; 79.1%) and the whirlpool sign (139/153; 90.8%) were the most commonly detected features of adnexal torsion.

Conclusion Most patients with surgically confirmed adnexal torsion are of reproductive age and present with acute or subacute pain. Common ultrasound signs are an enlarged adnexa, the whirlpool sign, ovarian stromal edema with or without peripherally displaced antral follicles and free fluid in the pelvis. The follicular ring sign and absence of Doppler signals in the twisted organ are slightly less common signs. Recognizing ultrasound signs of adnexal torsion is important so that the correct treatment, i.e. surgery without delay, can be offered. Copyright © 2020 ISUOG. Published by John Wiley & Sons Ltd.

INTRODUCTION

Aim

The aim of this study was to describe the clinical and ultrasound characteristics of adnexal torsion.

Background

Epidemiology

Adnexal torsion is one of the most common causes of acute pelvic pain in non-pregnant women, preceded by corpus luteum rupture with hemorrhage, and followed by pelvic inflammatory disease, malpositioned intrauterine device and degenerating fibroids¹. It is most common in women of reproductive age^{2–4}, but can occur in children^{5,6} and rarely in postmenopausal women^{2,7,8}. A national population-based study from Korea reported an incidence of adnexal torsion of nine per 100 000 women per year⁹, whereas a population-based matched cohort study in 8 532 163 pregnant women reported an incidence of adnexal torsion of 16 per 100 000 during 8 years¹⁰.

Adnexal torsion is defined as rotation of the adnexal supporting structures (infundibulopelvic ligament and tubo-ovarian ligament) around their vascular axis. The severity of the vascular impairment is variable, depending on the number of twists and the tightness at the neck of the torsion, which can cause partial or complete vascular obstruction¹¹. In some cases, only the ovary is twisted, but in other cases, both the ovary and the Fallopian tube are involved. Torsion involving only the Fallopian tube has also been described^{12–14} in association with

tubal pathology (hydrosalpinx or hematosalpinx) or with adnexal masses, e.g. paraovarian or paratubal cysts^{15,16}. Only a few cases of torsion involving only paratubal or paraovarian cysts have been reported in the literature^{11,17}.

An important risk factor for adnexal torsion is previous adnexal torsion. Some studies reported that 11–19% of patients with adnexal torsion had previous adnexal torsion^{6,18,19}. Patients who have had torsion of a normal adnexa have a higher risk of recurrent torsion than do patients who have had torsion of an adnexal cyst^{11,19}. Other reported risk factors are pregnancy and conditions that are associated with enlarged ovaries, such as adnexal masses, ovarian hyperstimulation and polycystic ovary^{20–22}.

Adnexal masses that twist are usually benign, with dermoid cyst and serous cystadenoma being the most commonly found pathology^{2–4}. Torsion is unusual in patients affected by endometriosis or by malignant lesions, most probably because of the increased likelihood of local inflammation and adhesions that fix the mass^{21,23}. During pregnancy, adnexal torsion occurs most frequently in the first trimester, probably because of the high prevalence of functional ovarian cysts¹¹. An enlarged corpus luteum is the most common finding in pregnant women with adnexal torsion^{24,25}. Adnexal torsion occurs in 0.8–0.13% of women with ovarian hyperstimulation caused by treatment for infertility^{26,27}. There is a right-sided predominance of adnexal torsion and various explanations have been proposed. A common explanation is that the decreased space in the left side of the pelvis, due to the presence of the sigmoid colon, decreases the risk of torsion^{4,23,28,29}.

Microscopy

Adnexal torsion is characterized by strangulation of the ovarian pedicle, affecting the blood flow. Lymphatic and venous flows are compromised first, because the walls of lymphatic vessels and veins are thinner and more compressible than those of the arteries. This causes vascular congestion and ovarian edema¹¹. If the torsion remains untreated, the edema compromises the arterial flow, causing arterial stasis, which leads to hemorrhagic infarction and necrosis of the ovarian parenchyma. Hemorrhagic necrosis is a common pathological finding, appearing as diffuse extravasation of red blood cells and variable degrees of devitalized ovarian tissue³⁰.

Macroscopy

On gross examination, the twisted organ appears enlarged due to engorgement, edema and ischemia, with bluish-black coloration and distinct hemorrhagic foci^{31,32}. The black–blue colored surface is explained by hemorrhagic congestion and necrosis^{33,34}.

Clinical features and prognosis

Most (94–100%) patients with adnexal torsion are symptomatic and the most common symptom is acute

pelvic pain^{4,35–37}. The pain may be constant or intermittent as the adnexa can twist and untwist^{38,39}. Nausea and vomiting are present in 70% of cases, explained by a vagal reflex secondary to intense pain or by peritoneal irritation^{5,20,28,35}. Fever and restlessness develop in rare cases⁴⁰.

In patients of reproductive age, the surgical management of adnexal torsion should be untwisting of the organ or lesion and excision of an adnexal mass if present. A laparoscopic approach is preferable, whenever possible³². Preservation of ovarian function has been reported in 88% to 100% of cases after untwisting of the ovary^{32,41}. An ultrasound examination should be performed 4–6 weeks after the untwisting procedure, to document the preservation of the ovarian parenchyma, by assessing ovarian size, vascularization and follicular development^{16,32}. Conservative treatment of ovarian torsion, via ultrasound-guided transabdominal cyst aspiration, represents a reasonable alternative to surgical intervention in pregnant patients⁴².

In postmenopausal women, unilateral salpingo-oophorectomy is justified due to a higher risk of malignancy and for prevention of recurrence. The decision regarding bilateral salpingo-oophorectomy should be made after discussing the potential risks and benefits with the patient⁷.

METHODS

This was a retrospective study performed in eight ultrasound centers (Rome, Bangalore (two centers), Coimbatore, London, Milan, Stockholm and Cagliari). From the operative records of the participating centers, patients with surgically confirmed adnexal torsion, who had undergone preoperative ultrasound examination by an experienced ultrasound examiner between 2008 and 2018, were identified. The study was approved by the Institutional Review Board of the study co-ordinator center.

To be included in the study, the patient needed to have a surgical diagnosis of adnexal torsion, defined as evidence of ovarian pedicle, paraovarian cyst and/or Fallopian tube twisted on its own axis. Moreover, only patients with at least two available ultrasound images and/or videoclips (one grayscale and one with Doppler evaluation) were included. All patients had been examined preoperatively with transvaginal, transrectal or transabdominal ultrasound using a standardized examination technique⁴³. The ultrasound examinations were carried out using high-end ultrasound equipment; the frequency of the transvaginal probes varied between 5.0 and 9.0 MHz and that of the transabdominal probes between 3.5 and 5.0 MHz. All ultrasound examiners had more than 10 years' experience in gynecological ultrasound.

For all patients, clinical, ultrasound, surgical and histological information was retrieved from their medical records and ultrasound reports and entered into an Excel file by the principal investigator at each center. The following clinical information was recorded: parity, menopausal status, previous gynecological surgery, history of adnexal

mass, adnexal torsion, pelvic inflammatory disease, tubal ligation or endometriosis, history of or current treatment with assisted reproductive techniques, ongoing estrogen or gestagen therapy and cancer antigen 125 (CA125) at diagnosis. Symptoms were also documented, pelvic pain in particular. Acute pelvic pain was defined as the sudden onset of lower abdominal or pelvic pain lasting less than 3 months, and as subacute if it lasted between 3 and 6 months⁴⁴. Chronic pelvic pain was defined as intermittent or constant pain in the lower abdomen or pelvis for at least 6 months, not occurring exclusively during menstruation or intercourse, and not associated with pregnancy⁴⁵. Recurrent abdominal pain was defined as at least three episodes of abdominal pain over a period of at least 3 months and severe enough to affect daily activities⁴⁶. Information on the surgical approach when treating the torsion, the type of operation and final histology (when present), as judged by the local pathologist, was also retrieved.

The following ultrasound information was recorded for each patient: organ judged to be involved in the torsion (Fallopian tube, ovary or paraovarian cyst), size of the twisted organ or lesion, free fluid in the pelvis and position of the twisted organ with respect to the uterus (anterior, posterior or lateral). In cases of lateral position, we specified whether the position of the twisted organ was ipsi- or contralateral with respect to the involved adnexa. When described in the original ultrasound report, the presence of the following ultrasound signs of adnexal torsion was noted: ovarian stromal edema with or without peripherally displaced antral follicles^{47,48} (Videoclip S1), the follicular ring sign i.e. hyperechogenic rim of follicle⁴⁹ (Videoclip S2), the whirlpool sign^{50–52} (Videoclip S3), absence of vascularization on Doppler examination^{45,48,53–56} (Videoclips S4 and S5) and tenderness of the organ suspected to be twisted when touched with the transvaginal probe or the outer free hand. The specific diagnosis suggested by the original ultrasound examiner in the original ultrasound report, according to pattern recognition, was also recorded. In cases of bilateral adnexal torsion detected on ultrasound, the adnexa with the largest diameter was used in the statistical analysis. If there was an adnexal mass, the International Ovarian Tumor Analysis (IOTA) terminology⁴³ had been used in the ultrasound report to describe the ultrasound image of the mass.

In addition to retrieving information from patient records and ultrasound reports, two authors with more than 10 years' experience in gynecological ultrasound (A.C.T. and F.M.), reviewed retrospectively all the ultrasound images and videoclips of the twisted adnexa with regard to the presence of four predefined ultrasound features reported to be characteristic of adnexal torsion: (1) ovarian stromal edema with or without peripherally displaced antral follicles, (2) the follicular ring sign, (3) the whirlpool sign and (4) absence of vascularization in the twisted organ. If the images/videoclips did not contain the information necessary to judge on the presence or absence of these predefined ultrasound features, the reviewers classified the feature as not assessable.

Results are presented as *n* (%) and as median (range) for discrete and continuous variables, respectively. All statistical calculations were performed using Stata software version 13.0 (Stata Corp., College Station, TX, USA).

RESULTS

We identified 315 patients, with adnexal torsion and available grayscale and Doppler ultrasound images and/or videoclips, from the databases of the participating centers. Seven (2.2%) of the 315 patients were included in the IOTA phase-5 study⁵⁴. Demographic background data and clinical characteristics of the patients are shown in Table 1. The median age was 30 (range, 1–88) years and most (284/314; 90.4%) patients were premenopausal. Almost all (305/315; 96.8%) patients presented with acute or subacute pelvic pain and 187/313 (59.7%) had nausea/vomiting.

Table 1 Clinical characteristics of 315 patients with adnexal torsion

Characteristic	Value
Age (years)	30 (1–88)
Nulliparous	144/296 (48.6)
Contemporaneous estrogen or gestagen therapy	29/293 (9.9)
Premenopausal	284/314 (90.4)
Previous surgery	
Hysterectomy	9 (2.9)
Unilateral salpingo-oophorectomy	10 (3.2)
Unilateral or bilateral cystectomy	12/297 (4.0)
Other pelvic surgery	27/295 (9.2)
Presence of adnexal mass known before torsion symptoms developed	31/293 (10.6)
Previous adnexal torsion	14/297 (4.7)
Previous ART of any type	9/266 (3.4)
Ongoing ART of any type	10/296 (3.4)
Previous ovarian hyperstimulation syndrome	2/266 (0.8)
Current ovarian hyperstimulation syndrome	8/296 (2.7)
History of polycystic ovary syndrome	30/286 (10.5)
History of tubal ligation	23/295 (7.8)
History of endometriosis	5/292 (1.7)
History of pelvic inflammatory disease	4/287 (1.4)
CA125 (U/mL)*	10.8 (0–448)
History of pain triggered by activity	16/286 (5.6)
History of similar episode of pain	45/289 (15.6)
Symptoms	
Acute or subacute pelvic pain	305 (96.8)
Chronic pelvic pain	2/309 (0.6)
Recurrent pelvic pain	8/309 (2.6)
Laterality of pain	
Right	143/237 (60.3)
Left	94/237 (39.7)
Abdominal distension	37/314 (11.8)
Fever	13/309 (4.2)
Nausea/vomiting	187/313 (59.7)
Other	35/312 (11.2)
Patient included in IOTA studies (IOTA5)	7 (2.2)

Data are given as median (range), *n/N* (%) or *n* (%). For categorical variables, denominators differ due to missing data. *Measured \leq 3 days before or after ultrasound examination. ART, assisted reproductive techniques; CA125, cancer antigen 125; IOTA, International Ovarian Tumor Analysis.

Surgical and histological findings are shown in Table 2. The surgical approach was laparoscopic in most (239/312; 76.6%) cases. The organs/lesions involved in the twisting were only the ovary in 143/313 (45.7%) patients, both the ovary and the Fallopian tube in 112/313 (35.8%) patients,

Table 2 Surgical and histological characteristics of 315 patients with adnexal torsion

Characteristic	Value
Type of surgery	
Laparoscopy	239/312 (76.6)
Laparotomy	73/312 (23.4)
Laterality of twisted adnexa	
Right	181 (57.5)
Left	132 (41.9)
Bilateral	2 (0.6)
Organ involved in torsion	
Only ovary	143/313 (45.7)
Only Fallopian tube	29/313 (9.3)
Both ovary and Fallopian tube	112/313 (35.8)
Paraovarian cyst	14/313 (4.5)
Other*	15/313 (4.8)
Surgical procedure	
Unilateral salpingo-oophorectomy	87 (27.6)
Untwisting†	75 (23.8)
Untwisting + excision of lesion‡	74 (23.4)
Unilateral oophorectomy	43 (13.7)
Bilateral salpingo-oophorectomy	10 (3.2)
Hysterectomy + bilateral adnexectomy	7 (2.2)
Debulking surgery	4 (1.3)
Unilateral salpingectomy	5 (1.6)
Unilateral salpingectomy + paraovarian cyst excision	4 (1.3)
Bilateral oophorectomy	3 (1.0)
Bilateral salpingectomy	1 (0.3)
Paraovarian cyst excision	1 (0.3)
Bilateral salpingectomy + paraovarian cyst excision	1 (0.3)
Excised tissue sent for histological examination	240 (76.2)
Histology in cases of excised tissue	
Ovary	
No mass	38/240 (15.8)
Benign mass	
Serous/mucinous cystadenoma	49/240 (20.4)
Dermoid cyst	43/240 (17.9)
Ovarian fibroma	11/240 (4.6)
Other	25/240 (10.4)
Borderline	
Serous or mucinous	3/240 (1.3)
Malignant mass	4/240 (1.7)
Fallopian tube	
No lesion	2/240 (0.8)
Hydrosalpinx	14/240 (5.8)
Other (paratubal/fimbrial cyst or ectopic pregnancy)	8/240 (3.3)
Paraovarian cyst§	18/240 (7.5)
Adnexa with no cyst + tubal torsion with no lesion	6/240 (2.5)
Paraovarian cyst§ + tubal lesion	18/240 (7.5)
Acute pelvic inflammatory disease	1/240 (0.4)
Histological signs consistent with torsion¶	169/209 (80.9)

Data are given as *n/N* (%) or *n* (%). For categorical variables, denominators differ due to missing data. *Seven cases involving both paraovarian cyst and Fallopian tube, six cases involving paraovarian cyst and ovary and two cases involving paraovarian cyst and hydrosalpinx. †With drainage in three cases. ‡Three cases also underwent unilateral salpingectomy and one also underwent oophorectomy. §All paraovarian cysts benign. ¶Ischemia, necrosis, hemorrhage, infarction.

only the Fallopian tube in 29/313 (9.3%), paraovarian cyst in 14/313 (4.5%) patients and other in 15/313 (4.8%) patients (paraovarian cyst and Fallopian tube in seven cases, paraovarian cyst and ovary in six cases and paraovarian cyst and hydrosalpinx in two cases). Conservative surgery (untwisting with or without excision of the lesion) was performed in 149/315 (47.3%) patients. Final histology was reported in 240/315 (76.2%) cases, while 75/315 (23.8%) underwent adnexal untwisting only, without excision of tissues. According to histological examination of excised tissues, most (135/240; 56.3%) patients with adnexal torsion had an ovarian mass, 22/240 (9.2%) had a tubal lesion/hydrosalpinx, 18/240 (7.5%) had a paraovarian cyst, 18/240 (7.5%) had both a paraovarian cyst and tubal lesion, 1/240 (0.4%) had acute pelvic inflammatory disease and in 46/240 (19.2%) patients no adnexal pathology was reported. Among patients with an ovarian mass, 128/135 (94.8%) had benign histology.

The sonographic characteristics of the twisted adnexa are shown in Table 3. The median largest diameter of the twisted organ, as measured on ultrasound, was 83 (range, 30–349) mm and the median largest diameter of an adnexal mass, if present, was 77 (range, 20–349) mm. Most adnexal lesions were classified as unilocular cysts (102/160; 63.8%) (Figure 1) and the cyst fluid was most often described as anechoic (94/204; 46.1%). Free fluid in the pouch of Douglas was detected in 196/275 (71.3%) patients. The position of the twisted organ, with respect to the uterus, was anterior in 44/246 (17.9%) patients, posterior in 54/246 (22.0%) patients and lateral in 148/246 (60.2%) patients, with ipsilateral or contralateral location, with respect to the involved adnexa, in 139/246 (56.5%) and 9/246 (3.7%), respectively. There was no information available on the site of the twisted adnexa in 69/315 (21.9%) cases.

Information on the presence/absence of ovarian stromal edema with or without peripherally displaced antral follicles was available in the original ultrasound reports for 241/315 patients and was reported as present in 167/241 (69.3%) (Figure 2). Information on the follicular ring sign was available in 134/315 patients and was reported as present in 51/134 (38.1%) (Figure 3). Information on the whirlpool sign was available in 226/315 patients, and it was reported as present in 178/226 (78.8%) (Figure 4). Information on Doppler signals in the twisted organ was available in 269/315 patients, and were reported as absent in 119/269 (44.2%) (Figure 5). Information on tenderness of the organ/lesion suspected to be twisted, when touched with the transvaginal probe or operator's free hand was available in 211/315 patients and was reported as present in 164/211 (77.7%). The original examiner was certain of the diagnosis of torsion in most (269/315; 85.4%) cases. Among the cases with invasive histology, the examiners suggested malignancy in two of three cases with invasive cancer (ovarian choriocarcinoma and immature teratoma) and they did not report any ultrasound features of torsion; in one invasive case (mucinous

Table 3 Ultrasound characteristics in 315 patients with adnexal torsion, as described in original ultrasound report

Characteristic	Value
Laterality of torsion	
Right	168/307 (54.7)
Left	131/307 (42.7)
Uncertain	7/307 (2.3)
Bilateral*	1/307 (0.3)
Organ involved in torsion	
Ovary	203/302 (67.2)
Fallopian tube	24/302 (7.9)
Paraovarian lesion	14/302 (4.6)
Combination of any of above	61/302 (20.2)
Largest diameter of twisted organ (mm)†	83 (30–349)
Largest diameter of ovary on side of torsion (mm)‡	78 (20–349)
Largest diameter of adnexal mass/lesion if present (mm)§	77 (20–349)
IOTA morphological classification of adnexal mass involved in twisted organ if present	
Unilocular	102/160 (63.8)
Multilocular	23/160 (14.4)
Unilocular-solid	11/160 (6.9)
Multilocular-solid	8/160 (5.0)
Solid	16/160 (10)
Specific diagnosis of adnexa involved in torsion, according to pattern recognition	
Twisted ovary without any mass	15/168 (8.9)
Dermoid cyst	39/168 (23.2)
Fibroma	11/168 (6.5)
Mucinous cystoadenoma	26/168 (15.5)
Hemorrhagic cyst	17/168 (10.1)
Endometrioma	1/168 (0.6)
Hydrosalpinx or paraovarian cyst	47/168 (28.0)
Ectopic pregnancy	1/168 (0.6)
Hyperstimulated ovary	1/168 (0.6)
Borderline tumor	6/168 (3.6)
Primary ovarian cancer	4/168 (2.4)
Free fluid in pelvis	196/275 (71.3)
Echogenicity of cyst fluid of twisted mass if cyst fluid present	
Anechoic	94/204 (46.1)
Low-level	61/204 (29.9)
Ground-glass	5/204 (2.5)
Mixed	44/204 (21.6)
Location of twisted organ	
Anterior to uterus	44/246 (17.9)
Posterior to uterus	54/246 (22.0)
Ipsilateral to side of involved adnexa	139/246 (56.5)
Contralateral to side of involved adnexa	9/246 (3.7)
Ovarian stromal edema with or without peripherally displaced antral follicles	167/241 (69.3)
Follicular ring sign	51/134 (38.1)
Whirlpool sign	178/226 (78.8)
No detectable Doppler signals in twisted organ	119/269 (44.2)
Tenderness of organ/lesion suspected to be twisted¶	164/211 (77.7)
Examiner certainty of ultrasound diagnosis of torsion	
Certain	269 (85.4)
Uncertain (e.g. torsion cannot be excluded)	18 (5.7)
No sign of torsion	1 (0.3)
Torsion not mentioned as possible diagnosis	24 (7.6)
Report not interpretable in this regard	3 (1.0)

Data are given as *n/N* (%), median (range) or *n* (%). For categorical variables, denominators differ due to missing data. *Bilateral torsion detected surgically in two cases, but described in ultrasound report in only one case. †Information available for 312 cases. ‡Information available for 295 cases. §Information available for 250 cases. ¶When touched with transvaginal probe or operator's free hand. IOTA, International Ovarian Tumor Analysis.

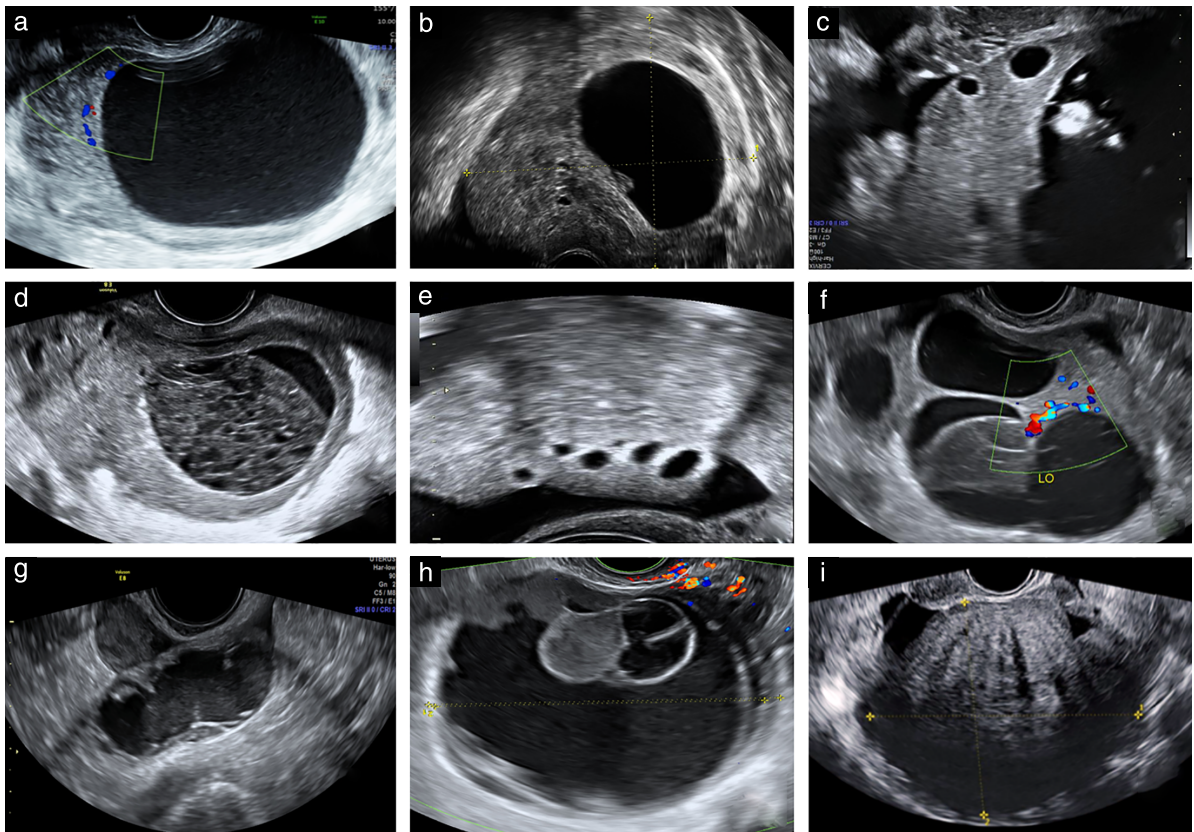


Figure 1 Ultrasound images of twisted ovaries with adnexal masses: (a,b,f) serous cystadenomas; (c,e) mature cystic teratoma; (d) corpus luteum; (g) Fallopian tube with pyosalpinx; (h) mucinous borderline tumor; and (i) fibroma. Ovarian stromal edema with or without peripherally displaced antral follicles is seen in (a–f) and follicular ring sign is seen in (c–e).

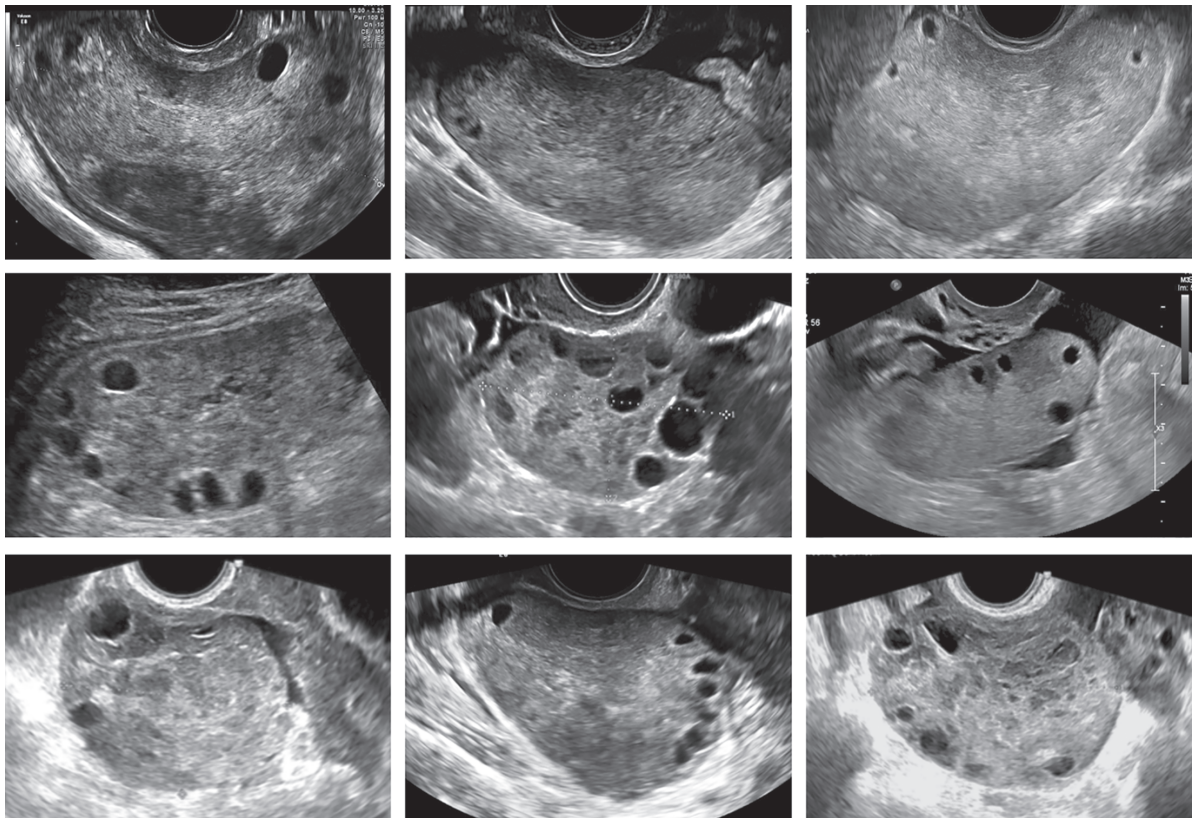


Figure 2 Ultrasound images of twisted adnexa, showing ovarian stromal edema with or without peripherally displaced antral follicles.

adenocarcinoma), the examiner suggested benign histology and reported stromal edema. Among four cases with borderline histology, the examiners classified correctly three cases as borderline, of which two had evidence of torsion (whirlpool sign in one case and edema in the other) and misdiagnosed one case as benign with no sign of torsion.

On retrospective review of the images and videoclips from the 315 patients, predefined features of torsion could not be assessed in all cases but, in those that could, ovarian stromal edema with or without peripherally displaced antral follicles (201/254; 79.1%) and the whirlpool sign (139/153; 90.8%) were the most common ultrasound signs of adnexal torsion (Table 4).

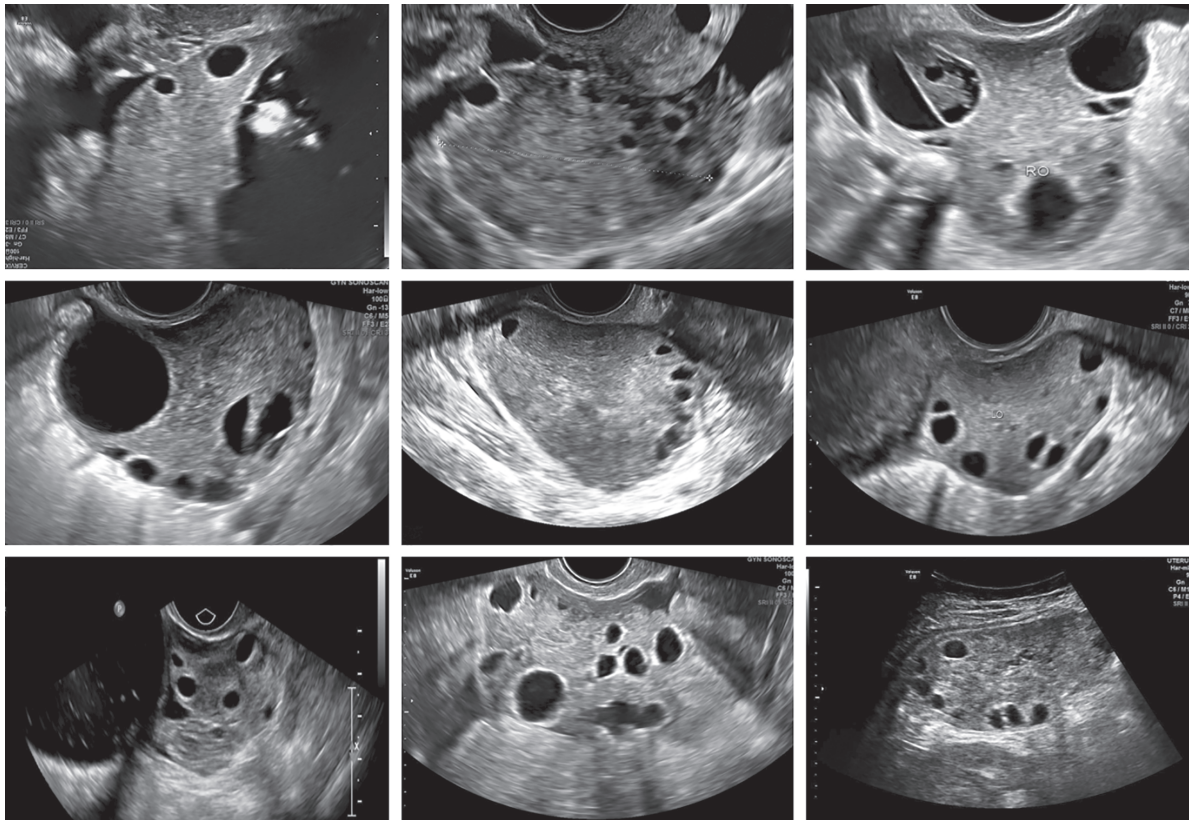


Figure 3 Ultrasound images of twisted adnexa manifesting follicular ring sign. LO, left ovary; RO, right ovary.

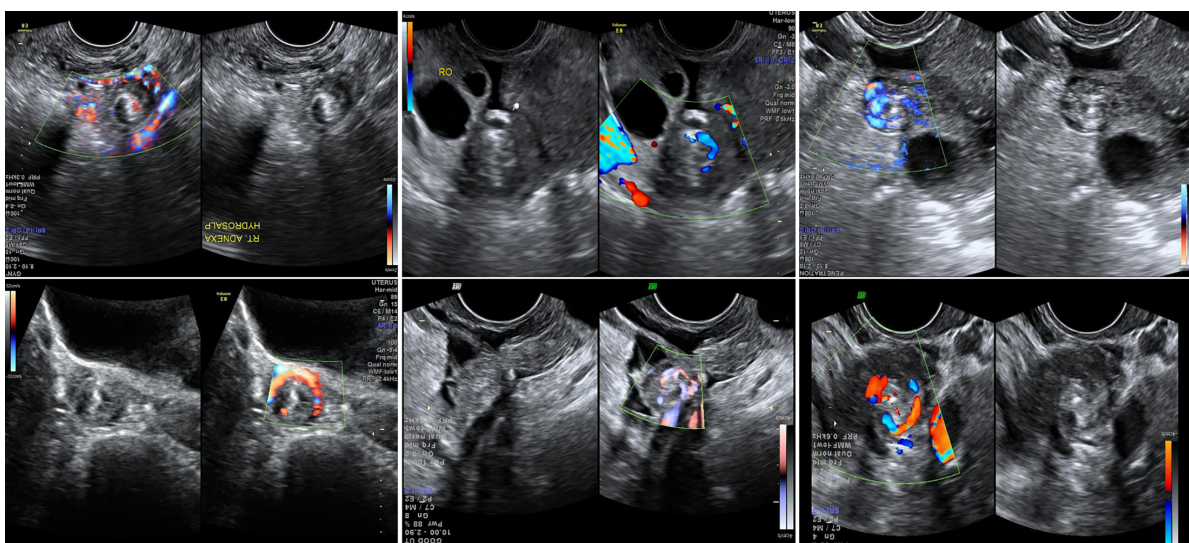


Figure 4 Ultrasound images of twisted adnexa manifesting whirlpool sign.

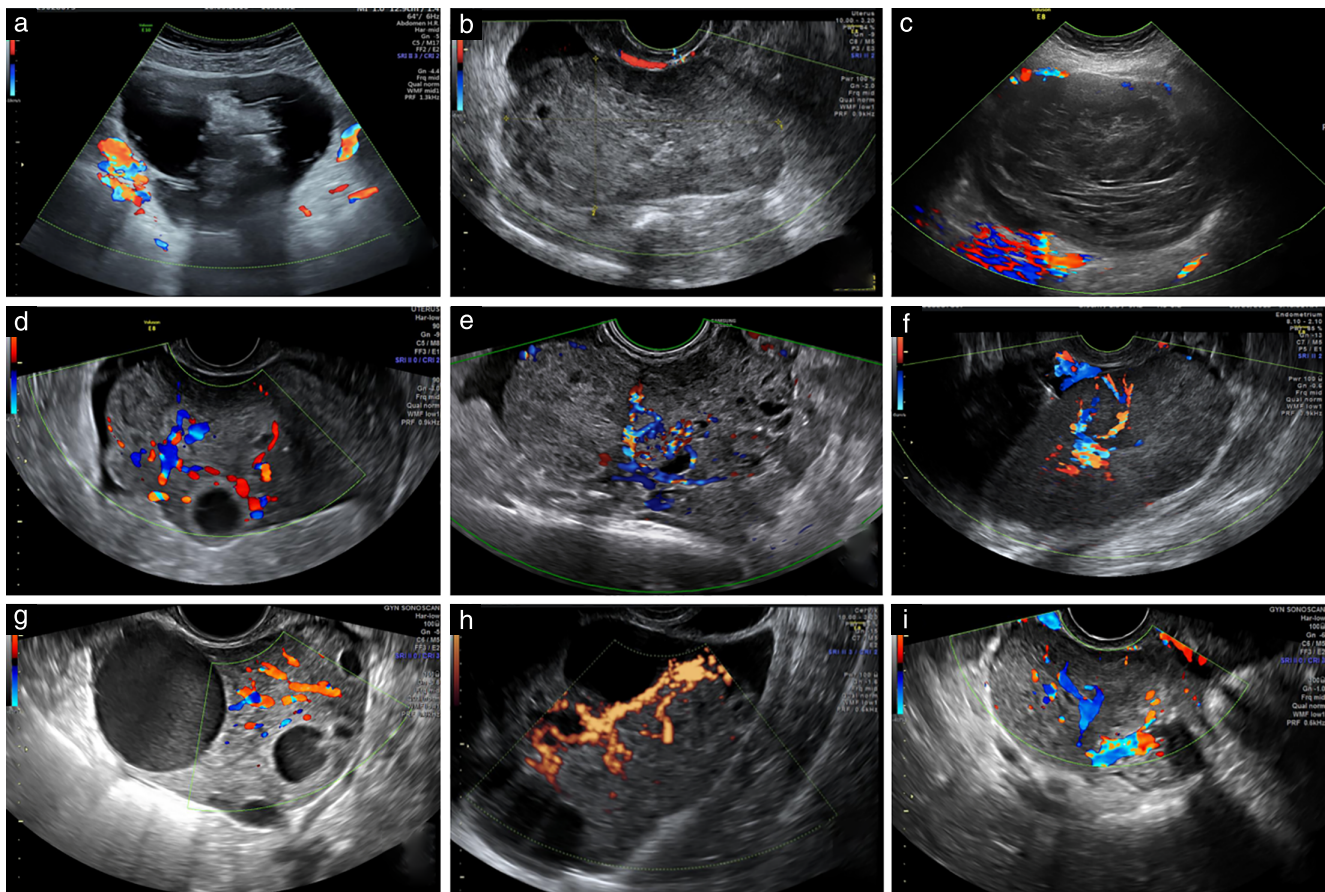


Figure 5 Color Doppler images of twisted adnexa without (a–c) and with (d–i) vascularization.

Table 4 Ultrasound features of adnexal torsion on review of images and videoclips from 315 patients, by two experienced ultrasound examiners

Characteristic	Value
Ovarian stromal edema with or without peripherally displaced antral follicles	201/254 (79.1)
Follicular ring sign	88/178 (49.4)
Vascularization absent on color Doppler	145/277 (52.3)
Whirlpool sign	139/153 (90.8)

Data are given as *n/N* (%). Prevalence of parameters calculated using only cases with images/videoclips of sufficient quality to allow reliable assessment.

DISCUSSION

In this study, we have described the clinical, surgical, histological and ultrasound characteristics of surgically confirmed adnexal torsion. The median age of the patients was 30 years and 90% were premenopausal. All patients were symptomatic and the most common presenting symptom was acute or subacute pelvic pain. At surgery, the organs involved in the twisting were the ovary only or both the ovary and Fallopian tube in most cases, and most surgically removed lesions were benign. On ultrasound, the most common finding was an enlarged adnexa, with an ovarian mass characterized by ovarian stromal edema with or without peripherally displaced antral follicles, the whirlpool sign and free fluid in the pelvis.

To the best of our knowledge, this is the largest study describing ultrasound findings in adnexal torsion. Review of ultrasound images or videoclips as a complement to the review of original ultrasound reports is another strength. A limitation of this study is that it is retrospective; some clinical, surgical and ultrasound information could not be retrieved for all cases. It is possible that the original examiners did not always note the presence or absence of the predefined ultrasound features of adnexal torsion in their report, even if they did use these signs to assess the diagnosis of adnexal torsion. Although ultrasound images and/or videoclips were available for all patients, the predefined ultrasound features of adnexal torsion could not always be assessed on retrospective review, because of insufficient information in the saved images. This may have limited the possibility to describe correctly the ultrasound features of adnexal torsion. Moreover, when reviewing saved images, the ultrasound examiners knew the diagnosis. This may have introduced bias that could explain why the whirlpool sign and ovarian stromal edema with or without peripherally displaced antral follicles were more common on review of the images than in the original ultrasound reports. Because of our study design, we cannot report on the sensitivity and specificity of ultrasound with regard to diagnosing adnexal torsion. Sensitivity and specificity can be estimated only in a prospective study; however, before starting a prospective

study, the typical ultrasound characteristics of adnexal torsion should be known.

Our results are in agreement with information in publications describing the clinical and histological characteristics of adnexal torsion, in that most patients were symptomatic^{35,36,52,57}, adnexal torsion was diagnosed mainly in premenopausal women²⁻⁴ and most surgically removed twisted ovarian lesions were benign, with cystadenomas and dermoid cysts being the most common^{2-4,23}. In this series, 38% (121/315) of patients had torsion of normal adnexa, as documented by the number of cases treated only with untwisting of the adnexa and the number of cases with no pathology at histology. This is a slightly lower rate than that reported in the literature²³. Among the 121 patients with no evidence of adnexal pathology, 112 had evidence of the whirlpool sign and/or ovarian stromal edema with or without peripherally displaced antral follicles; in the remaining nine patients, the original examiner reported enlarged adnexa associated with pelvic pain, but no other ultrasound sign of torsion. Among patients with final histology, the vast majority (81%) of the adnexa manifested histological signs consistent with torsion. In cases (19%) with no evidence of specific histological signs of torsion (ischemia, necrosis, hemorrhage or infarction), we suspect that the pathologist described the nature only of the surgically removed adnexal lesion.

Untwisting of the twisted organ is recommended as the standard surgical treatment for patients with adnexal torsion³². In this series, only 45% of patients were managed with untwisting (or untwisting plus excision of the lesion) only, probably because conservative management was considered inappropriate in some patients, e.g. in postmenopausal patients or in patients with suspicion of malignancy on ultrasound or frozen section. In other cases, the surgeon probably decided not to manage conservatively because of necrotic appearance of the twisted organ. However, recent studies support conservative management with untwisting in premenopausal patients, even if there are signs of organ necrosis³². Ovarian function after untwisting has been documented in 93–100% of cases reported as necrotic at macroscopic assessment^{19,32,43}. In patients with a twisted ovarian mass or twisted paraovarian cyst, the appropriate treatment should be surgical excision of the mass and untwisting of the residual ovarian parenchyma. In cases of a twisted tube with no lesion, conservative management in premenopausal patients is preferred over surgical removal of the tube, whereas in cases of a twisted hydrosalpinx, removal of the organ is recommended^{58,59}.

Several studies have described the sonographic appearance of adnexal torsion, but most are small and described few ultrasound features^{28,34,47-49,53,60,61}. The largest series was reported by Mashiach *et al.*⁴⁷, including 47 patients with surgical confirmation of ovarian torsion. The most typical ultrasound findings of a twisted ovary were reported to be an enlarged ovary, ovarian edema and free fluid in the pelvis. Other studies focused only on the whirlpool sign and found it to be present in 88–100%

of patients with adnexal torsion^{13,50-52,62}. The follicular ring sign was first described by Sibal⁴⁹, who found it to be present in 12/15 (80%) patients with a diagnosis of ovarian torsion, and it was suggested that this feature is an early sign of torsion. Histological examination showed that the follicular ring sign was explained by edema, engorged capillaries and hemorrhage within the thecal layer of the follicles, as well as in the perifollicular region of the stroma immediately surrounding the follicles. On retrospective review of our images, we recognized the follicular ring sign in half of the cases. We noted absence of Doppler signals in the twisted adnexa in fewer than half of our patients, confirming that vascularization does not exclude torsion^{47,54-56,63}.

Recognizing ultrasound signs of adnexal torsion is important so that surgery is not delayed. The ultrasound examination may also provide information on the most likely origin of the twisted organ (ovary, tube or paraovarian cyst) and define its nature as benign, borderline or malignant. This allows planning of the most appropriate management. In cases of suspicion of a malignant ovarian tumor, the surgical treatment should include both resolution of the torsion and oncological surgical staging, if the diagnosis is made in an oncological center^{40,64}. Secondary-staging surgery in a gynecological oncology center should be planned after resolving the urgency, if the patient is treated initially in a unit not specialized in gynecological oncological surgery².


REFERENCES

1. Amirbekian S, Hooley RJ. Ultrasound evaluation of pelvic pain. *Radiol Clin North Am* 2014; 52: 1215–1235
2. Ozcan A, Mumusoglu S, Gokcu M, Caypinar SS, Sagioglu C, Inan AH, Aktöz F, Biler A, Turan V, Töz E, Ozdemir IA, Bozdog G. Differentiated therapy in pre- and postmenopausal adnexal torsion based on malignancy rates: A retrospective multicentre study over five years. *International Journal of Surgery* 2016; 29: 95–100.
3. Houry D, Abbott JT. Ovarian torsion: A fifteen-year review. *Ann Emerg Med* 2001; 38: 156–159.
4. Maheswari LS, Abraham R, Arunachalam P. Adnexal torsion-five-year retrospective study. *Int J Reprod Contracept Obstet Gynecol* 2018; 7: 508–512.
5. Melcer Y, Maymon R, Pekar-Zlotin M, Pansky M, Smorgick N. Clinical and sonographic predictors of adnexal torsion in pediatric and adolescent patients. *J Pediatr Surg* 2018; 53: 1396–1398.
6. Hubner N, Langer JC, Kives S, Allen LM. Evolution in the Management of Pediatric and Adolescent Ovarian Torsion as a Result of Quality Improvement Measures. *J Pediatr Adolesc Gynecol* 2017; 30: 132–137
7. Cohen A, Solomon N, Almog B, Cohen Y, Tsafir Z, Rimón E, Levin I. Adnexal Torsion in Postmenopausal Women: Clinical Presentation and Risk of Ovarian Malignancy. *J Minim Invasive Gynecol* 2017; 24: 94–97
8. Ganer HH, Shalev A, Ginath S, Kerner R, Keidar R, Bar J, Sagiv R. Clinical characteristics and the risk for malignancy in postmenopausal women with adnexal torsion. *Maturitas* 2015; 81: 57–61
9. Yuk JS, Kim LY, Shin JY, Choi DY, Kim TY, Lee JH. A national population-based study of the incidence of adnexal torsion in the Republic of Korea. *Int J Gynecol Obstet* 2015; 129: 169–170.
10. Bassi A, Czuzoj-Shulman N, Abenheim HA. Effect of Pregnancy on the Management and Outcomes of Ovarian Torsion: A Population-Based Matched Cohort Study. *J Minim Invasive Gynecol* 2018; 25:1260–1265.
11. Melcer Y, Sarig-Meth T, Maymon R, Pansky M, Vaknin Z, Smorgick N. Similar But Different: A Comparison of Adnexal Torsion in Pediatric, Adolescent, and Pregnant and Reproductive-Age Women. *J Womens Health* 2016; 25: 391–396.
12. Raban O, Zilber H, Hadar E, Efrat Z, Krissi H, Wiznitzer A, Meizner I, Bardin R. Isolated Fallopian Tube Torsion: A Unique Ultrasound Identity or a Serial Copycat? *J Ultrasound Med* 2018; 37: 2387–2393
13. Vijayaraghavan SB, Senthil S. Isolated Torsion of the Fallopian Tube: The Sonographic Whirlpool Sign. *J Ultrasound Med* 2009; 28: 657–662.
14. Comerci G., Colombo FM, Stefanetti M, Grazia G. Isolated fallopian tube torsion: a rare but important event for women of reproductive age. *Fertil Steril* 2008; 90: 1198.e23–25.
15. Kousari YMS, Pollock AN. Isolated Fallopian Tube Torsion With Paraovarian Cyst. *Pediatr Emerg Care* 2016; 32: 817–819.

16. Ding DC, Hsu S, Kao SP. Isolated Torsion of the Hydrosalpinx in a Postmenopausal Woman. *JLS 2007*; 11: 252–254.
17. Kiselí M, Caglar GS, Cengiz SD, Karadag D, Yılmaz MB. Clinical diagnosis and complications of paratubal cysts: review of the literature and report of uncommon presentations. *Arch Gynecol Obstet 2012*; 285: 1563–1569.
18. Beaunoyer M, Chapdelaine J, Bouchard S, Ouimet A. Asynchronous bilateral ovarian torsion. *J Pediatr Surg 2004*; 39: 746–749.
19. Pansky M, Smorgick N, Herman A, Schneider D, Halperin R. Torsion of Normal Adnexa in Postmenarchal Women and Risk of Recurrence. *Obstet Gynecol 2007*; 109: 355–359.
20. Asfour V, Varma R, Menon P. Clinical risk factors for ovarian torsion. *J Obstet Gynaecol 2015*; 35: 721–725.
21. Huchon C, Fauconnier A. Adnexal torsion: a literature review. *Eur J Obstet Gynecol Reprod Biol 2010*; 150: 8–12.
22. Tsafir Z, Azem F, Hasson J, Solomon E, Almog B, Nagar H, Lessing JB, Levin I. Risk Factors, Symptoms, and Treatment of Ovarian Torsion in Children: The Twelve-Year Experience of One Center. *J Minim Invasive Gynecol 2012*; 19: 29–33.
23. Oltmann SC, Fischer A, Barber R, Huang R, Hicks B, Garcia N. Cannot exclude torsion: a 15-year review. *J Pediatr Surg 2009*; 44: 1212–1217.
24. Koo YJ, Lee JE, Lim KT, Shim JU, Mok JE, Kim TJ. A 10-year experience of laparoscopic surgery for adnexal masses during pregnancy. *Int J Gynecol Obstet 2011*; 113: 36–39.
25. Hasiakos D, Papakonstantinou K, Kontoravdis A, Gogas L, Aravantinos L, Vitoratos N. Adnexal torsion during pregnancy: Report of four cases and review of the literature. *J Obstet Gynaecol Res 2008*; 34: 683–687.
26. Spitzer D, Wirlleitner B, Steiner H, Zech N. Adnexal Torsion in Pregnancy after Assisted Reproduction - Case Study and Review of the Literature. *Geburtshilfe Frauenheilkd 2012*; 72: 716–720.
27. Rackow BW, Patrizio P. Successful pregnancy complicated by early and late adnexal torsion after in vitro fertilization. *Fertil Steril 2007*; 87: 697.e9–12.
28. Warner MA, Fleischer AC, Edell SL, Thieme GA, Bundy AL, Kurtz AB, James AE. Uterine adnexal torsion: sonographic findings. *Radiology 1985*; 154: 773–775.
29. Sasaki KJ, Miller CE. Adnexal Torsion: Review of the Literature. *J Minim Invasive Gynecol 2014*; 21: 196–202.
30. Mneimneh WS, Nazeer T, Jennings TA. Torsion of the Gonad in the Pediatric Population: Spectrum of Histologic Findings with Focus on Aspects Specific to Neonates and Infants. *Pediatr Dev Pathol 2013*; 16: 74–79.
31. Chen M, Chen CD, Yang YS. Torsion of the previously normal uterine adnexa. *Acta Obstet Gynecol Scand 2001*; 80: 58–61.
32. Cohen SB, Wattiez A, Seidman DS, Goldenberg M, Admon D, Mashlach S, Oelsner G. Laparoscopy Versus Laparotomy for Detorsion and Sparing of Twisted Ischemic Adnexa. *JLS 2003*; 7: 295–299.
33. Chiou SY, Lev-Toaff AS, Masuda E, Feld RI, Bergin D. Adnexal Torsion: New Clinical and Imaging Observations by Sonography, Computed Tomography, and Magnetic Resonance Imaging. *J Ultrasound Med 2007*; 26: 1289–1301.
34. Singh N, McCluggage WG. Essentials of diagnostic gynecological pathology. In *Pathology of the ovary, fallopian tube and peritoneum*, Wilkinson N (ed). Springer-Verlag, London: 2014; 55.
35. White M, Stella J. Ovarian torsion: 10-year perspective. *Emerg Med Australas 2005*; 17: 231–237.
36. Dasgupta R, Renaud E, Goldin AB, Baird R, Cameron DB, Arnold MA, Diefenbach KA, Gosain A, Grabowski J, Guner JS, Jancelewicz T, Kawaguchi A, Lal DR, Oyetunji TA, Ricca RL, Shelton J, Somme S, Williams RF, Downard CD. Ovarian torsion in pediatric and adolescent patients: A systematic review. *J Pediatr Surg 2018*; 53: 1387–1391.
37. Ashwal E, Hirsch L, Krissi H, Eitan R, Less S, Wiznitzer A, Peled Y. Characteristics and Management of Ovarian Torsion in Premenarchal Compared With Postmenarchal Patients. *Obstet Gynecol 2015*; 126: 514–520.
38. Hyttel TEW, Bak GS, Larsen SB, Løkkegaard ECL. Re-torsion of the ovaries. *Acta Obstet Gynecol Scand 2015*; 94: 236–244.
39. Mehmetoğlu F. How can the risk of ovarian retorsion be reduced? *J Med Case Rep 2018*; 12: 200.
40. Eitan R, Galoyan N, Zuckerman B, Shaya M, Shen O, Beller U. The risk of malignancy in post-menopausal women presenting with adnexal torsion. *Gynecol Oncol 2007*; 106: 211–214.
41. Oelsner G, Shashar D. Adnexal Torsion. *Clin Obstet Gynecol 2006*; 49: 459–463.
42. Boswell KM, Silverberg KM. Recurrence of ovarian torsion in a multiple pregnancy: conservative management via transabdominal ultrasound-guided ovarian cyst aspiration. *Fertil Steril 2010*; 94: 1910e1–3.
43. Timmerman D, Valentin L, Bourne TH, Collins WP, Verrelst H, Vergote I. Terms, definitions and measurements to describe the sonographic features of adnexal tumors: a consensus opinion from the International Ovarian Tumor Analysis (IOTA) group. *Ultrasound Obstet Gynecol 2000*; 16: 500–505.
44. Abbott J, Won RH. Optimal management of chronic cyclical pelvic pain: an evidence-based and pragmatic approach. *Int J Womens Health 2010*; 2: 263–277.
45. Rousseau V, Massicot V, Darwish AA, Sauvat F, Emond S, Thibaud E, Nihoul-Fékété C. Emergency Management and Conservative Surgery of Ovarian Torsion in Children: A Report of 40 Cases. *J Pediatr Adolesc Gynecol 2008*; 21: 201–206.
46. Treede RD, Rief W, Barke A, Aziz Q, Bennett MI, Benoliel R, Cohen M, Evers S, Finnerup NB, First MB, Giamberardino MA, Kaasa S, Kosek E, Lavand'homme P, Nicholas M, Perrot S, Scholz J, Schug S, Smith BH, Svensson P, Vlaeyen JWS, Wang SJ. A classification of chronic pain for ICD-11. *Pain 2015*; 156: 1003–1007.
47. Mashlach R, Melamed N, Gilad N, Ben-Shitrit G, Meizner I. Sonographic Diagnosis of Ovarian Torsion: Accuracy and Predictive Factors. *J Ultrasound Med 2011*; 30: 1205–1210.
48. Chang HC, Bhatt S, Dogra VS. Pearls and Pitfalls in Diagnosis of Ovarian Torsion. *Radiographics 2008*; 28: 1355–1368.
49. Sibal M. Follicular ring sign: a simple sonographic sign for early diagnosis of ovarian torsion. *J Ultrasound Med 2012*; 31: 1803–1809.
50. Navve D, Hershkovitz R, Zetounie E, Klein Z, Tepper R. Medial or Lateral Location of the Whirlpool Sign in Adnexal Torsion: Clinical Importance. *J Ultrasound Med 2013*; 32: 1631–1634.
51. Valsky DV, Esh-Broder E, Cohen SM, Lipschuetz M, Yagel S. Added value of the gray-scale whirlpool sign in the diagnosis of adnexal torsion. *Ultrasound Obstet Gynecol 2010*; 36: 630–634.
52. Vijayaraghavan SB. Sonographic Whirlpool Sign in Ovarian Torsion. *J Ultrasound Med 2004*; 23: 1643–1649.
53. Shadinger LL, Andreotti RF, Kurian RL. Preoperative Sonographic and Clinical Characteristics as Predictors of Ovarian Torsion. *J Ultrasound Med 2008*; 27: 7–13.
54. Froyman W, Landolfo C, De Cock B, Wynants L, Sladkevicius P, Testa AC, Van Holsbeke C, Domali E, Fruscio R, Epstein E, Dos Santos Bernardo MJ, Franchi D, Kudla MJ, Chiappa V, Alcazar JL, Leone FPG, Buonomo F, Hochberg L, Coccia ME, Guerriero S, Deo N, Jokubkiene L, Kaijser J, Coosemans A, Vergote I, Verbakel JY, Bourne T, Van Calster B, Valentin L, Timmerman D. Risk of complications in patients with conservatively managed ovarian tumours (IOTA5): a 2-year interim analysis of a multicentre, prospective, cohort study. *Lancet Oncol 2019*; 20: 448–458.
55. Lee EJ, Kwon HC, Joo HJ, Suh JH, Fleischer AC. Diagnosis of ovarian torsion with color Doppler sonography: depiction of twisted vascular pedicle. *J Ultrasound Med 1998*; 17: 83–89.
56. Kupescic S, Plavsic BM. Adnexal torsion: color Doppler and three-dimensional ultrasound. *Abdom Imaging 2010*; 35: 602–606.
57. Rey-Bellet Gasser C, Gehri M, Joseph JM, Pauchard JY. Is It Ovarian Torsion? A Systematic Literature Review and Evaluation of Prediction Signs. *Pediatr Emerg Care 2016*; 32: 256–261.
58. Van der Zanden M., Nap A., Van Kints M. Isolated torsion of the fallopian tube: a case report and review of the literature. *Eur J Pediatr 2011*; 170:1329–1332.
59. Kinselí M, Caglar GS, Cengiz SD, Karadag D, Yılmaz MB. Clinical diagnosis and complication of paratubal cysts: review of the literature and report of uncommon presentation. *Arch Gynecol Obstet 2012*; 285: 1563–1569.
60. Stark JE, Siegel MJ. Ovarian torsion in prepubertal and pubertal girls: sonographic findings. *AJR Am J Roentgenol 1994*; 163: 1479–1482.
61. Nizar K, Deutsch M, Filmer S, Weizman B, Beloesky R, Weiner Z. Doppler studies of the ovarian venous blood flow in the diagnosis of adnexal torsion. *J Clin Ultrasound 2009*; 37: 436–439.
62. Valsky DV, Cohen SM, Hamani Y, Lipschuetz M, Yagel S, Esh-Broder E. Whirlpool sign in the diagnosis of adnexal torsion with atypical clinical presentation. *Ultrasound Obstet Gynecol 2009*; 34: 239–242.
63. Ben-Ami M, Perlit Y, Haddad S. The effectiveness of spectral and color Doppler in predicting ovarian torsion. A prospective study. *Eur J Obstet Gynecol Reprod Biol 2002*; 104: 64–66.
64. Osman B, Icen MS, Mahmoud AS, Capar M, Colakoglu MC. Management and outcomes of adnexal torsion: a 5-year experience. *Arch Gynecol Obstet 2011*; 284: 643–646.

SUPPORTING INFORMATION ON THE INTERNET

The following supporting information may be found in the online version of this article:

-  **Videoclips S1–S5** Ultrasound imaging of twisted ovary showing ovarian stromal edema with or without peripherally displaced antral follicles (Videoclip S1), showing follicular ring sign (Videoclip S2), showing whirlpool sign (Videoclip S3), with no vascularization (Videoclip S4), with vascularization (Videoclip S5).